

# Endocarditis (clinical lessons)

Jonathan Sandoe  
Consultant Microbiologist  
Leeds Teaching Hospitals NHS Trust,  
University of Leeds



# History

- PC: rigors, lethargy, nausea
- PMH:
  - Myelofibrosis 2011
  - BMT May 2014 (various complications inc GvHD)
  - Chronic thrombocytopenia
  - Aortic stenosis
  - Recurrent MDR *Pseudomonas aeruginosa* bacteraemia



# Examination

- No peripheral stigmata of IE
- Heart sounds: ESM + PSM (3-4/6)
- Chest clear
- Painless 3cm splenomegaly
- No peripheral oedema

AKI on admission



## Previous *Pseudomonas aeruginosa* bacteraemias

Date	Blood cultures	Sensitivities										Treatment
		CIP	PTA	CTZ	GEN	MER	IMI	TOB	AZT	AMI	FOS	
2/4/15	Line and peripheral	R	R	R	R	R		R		S		COL, Taurolock
26/7/15	Line and peripheral	R	R	R	R	R						MER and line removal
8/10/15	Peripheral	R	R	R	R			R	I	S		AMI 7/7
8/11/15	Peripheral	R	R		R	R	R	R	I	S		AMI and AZT 14/7. Discharged on IV AZT and FOS via CIVAS to complete 6/52*
12/12/15	Peripheral								I		S	
19/09/16 x4	peripheral	R >8	R 64	R 16	R >32	R 16	R 16	R >32	8 I	S 8	S	

\* Re-admitted with chest sepsis before finishing course.

# Investigations

05/2015: **TTE** - calcified AV, trivial thickening of MV

11/2015: **US abdo** enlarged spleen 19.6cm

11/2015: **TOE** Non-diagnostic

11/2015: **FDG PET-CT** No infective source identified

12/2015: **TTE** - calcified AV, trivial MR and TR

12/2015: **HRCT** pulmonary oedema

9/2016: **TTE** likely MV IE, severe MR, severe AS.

09/2016: **FDG PET/CT**: nil except splenic infarct

10/2016): **TOE** moderate/severe AS, vegetation MV



# Suitable for OPAT?

- Patient has previously had CIVAS
- Very happy with CIVAS service
- Wants to go home again



# Suitable for OPAT?

Which agent(s)?







# BSAC guidelines 2012

## Recommendation 5.11

- IE patients need to be generally suitable... 

## Recommendation 5.12

- IE patients who might be considered for HCOT
  - stable and responding well 
  - without signs of heart failure 
  - without indications for surgery 
  - without uncontrolled extra-cardiac foci 



# Indications for surgery

ESC, Habib 2015

Indications for surgery	Timing <sup>a</sup>
<b>1. Heart failure</b>	
Aortic or mitral NVE or PVE with severe acute regurgitation, obstruction or fistula causing refractory pulmonary oedema or cardiogenic shock	Emergency
Aortic or mitral NVE or PVE with severe regurgitation or obstruction causing symptoms of HF or echocardiographic signs of poor haemodynamic tolerance	Urgent
<b>2. Uncontrolled infection</b>	
Locally uncontrolled infection (abscess, false aneurysm, fistula, enlarging vegetation)	Urgent
Infection caused by fungi or multiresistant organisms	Urgent/ elective
Persisting positive blood cultures despite appropriate antibiotic therapy and adequate control of septic metastatic foci	Urgent
PVE caused by staphylococci or non-HACEK gram-negative bacteria	Urgent/ elective



# Management

## Deemed unsuitable to OPAT

### Antibiotics:

- Ceftolozane-tazobactam 1.5g 8-h IV
- Fosfomycin 8g 8-hourly IV

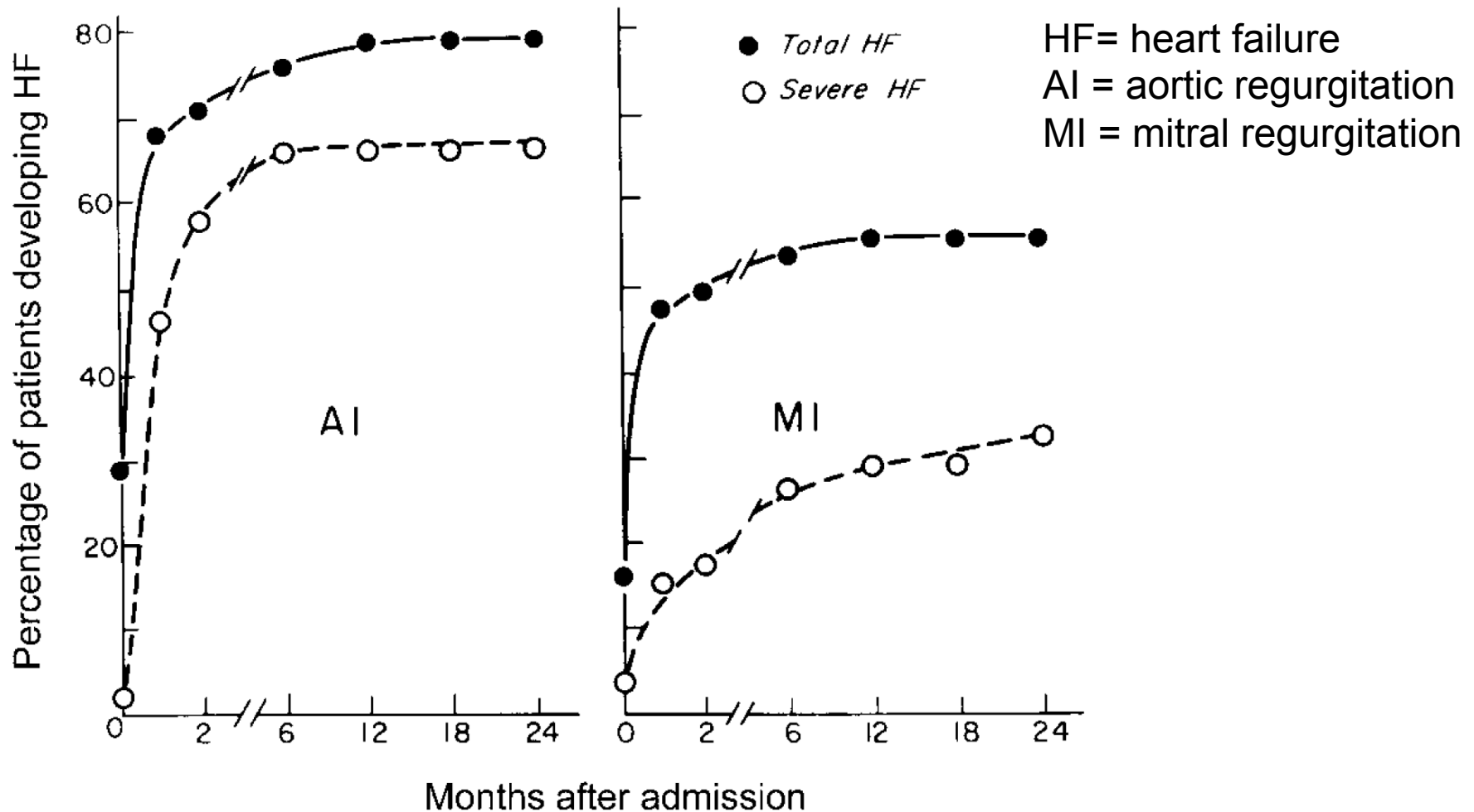
### Surgical:

- Severe MR – will need surgery at some point
- (Embolism to spleen)
- If therapy fails no further antibiotic options
- No known cases ceftolozane-tazobactam treatment of IE

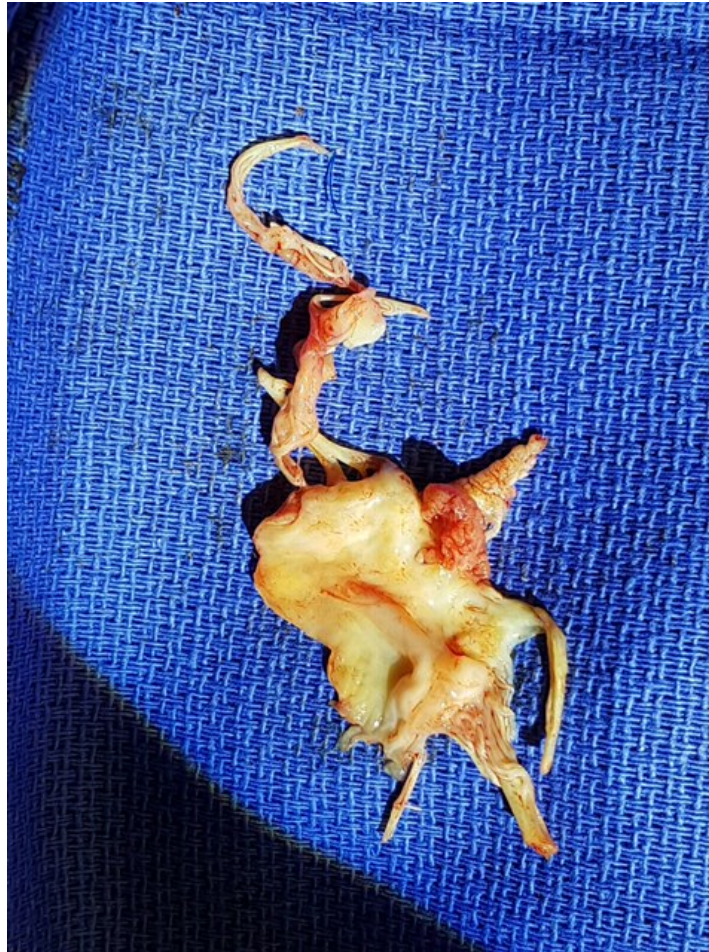

BSAC OPAT 2016

# Timing of heart failure in IE



# Excised mitral valve



# Suitable for OPAT?

- Patient has previously had CIVAS
- Very happy with CIVAS service
- Wants to go home again



# Suitable for OPAT?

Which agent(s)



# Summary

- *Pseudomonas aeruginosa* is a rare cause of IE
- MDR strains challenging to treat
- Surgery may become only option
- Indications for surgery change rapidly with time
- OPAT can be considered at different points during the course of treatment
- Multidisciplinary team decision making together with patient and family – very important

